

FREQUENTLY ASKED QUESTIONS for PEDIATRIC ULTRASOUND

Q. When should I order a testicular ultrasound for a non-palpable testis?

A. Testicular ultrasounds should not be routinely ordered for non-palpable testes. Often, our pediatric urologists do not find this imaging study helpful. It is preferred that the patient be seen in consultation, with the US exam ordered only if contributory information is anticipated by the consulting urologist.

Q. When should I order an ultrasound instead of CT scan to evaluate for possible cervical abscess?

A. An ultrasound should be requested when the patient has either a palpable lateral neck mass or a suspected lateral neck infection.

Q. Between what ages is a hip ultrasound useful to evaluate for hip dysplasia?

A. If the hip is stable, hip ultrasound is best ordered at 4-6 weeks of age in a term infant, minimizing false positive exams due to hip immaturity. Generally, hip ultrasound for hip dysplasia should not be ordered in infants over 4-6 months of age.

Q. Should an infant with a simple sacral dimple have a spine ultrasound to evaluate for possible tethered cord? At what age is an infant too old to have a spine ultrasound?

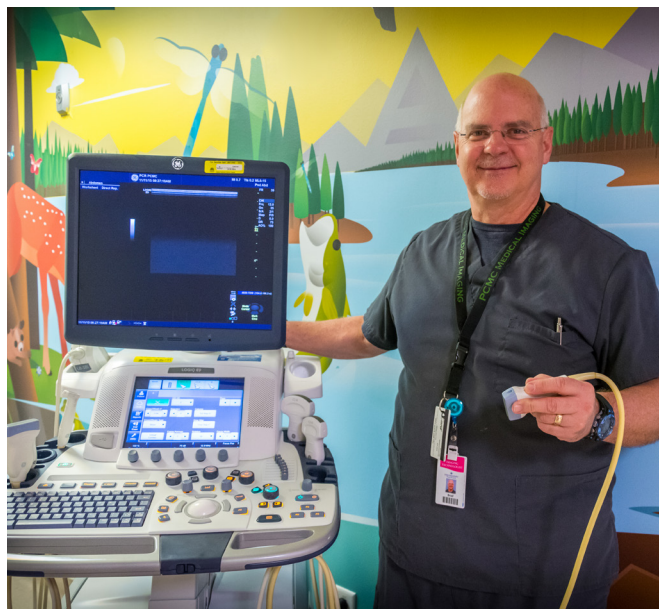
A. No. Infants with simple sacral dimple (midline, <5mm diameter, <2.5 cm above the anus) do not need a spine ultrasound. Their risk of tethered cord is ~0.13%. The maximum age for spine ultrasound is 4 months in a term infant.

Q. Is there a prep for abdominal ultrasound?

A. Patients should be fasting for an abdominal ultrasound, especially if there is any concern regarding the gall bladder. The NPO time varies with age and is available from the Medical Imaging schedulers.

Q. Is there a prep for a pelvic ultrasound?

A. The study requires a full bladder. When scheduled electively, complete the ingestion of 32 ounces of water 60 min prior to the exam time, and do not void.



Q. What age is too old for a head ultrasound?

A. A head ultrasound requires an open fontanelle. The larger the infant, the less optimal will be the resolution. The maximum age with an open fontanelle is generally 12 months. Because of the decreasing size of the fontanelle, the exam may be very limited after 8 months.

Q. Should I order an ultrasound or a CT scan for evaluation of appendicitis? Is an appendix ultrasound part of a routine abdominal or pelvis ultrasound?

A. Our imaging protocol for suspected appendicitis begins with ultrasound, in order to reduce patient radiation exposure and cost. The appendix ultrasound is not part of a routine abdominal or pelvic ultrasound. It must be ordered independently.

Q. Should I order a pyloric ultrasound or an upper GI to evaluate a vomiting infant?

A. Pyloric ultrasound should be ordered when your primary suspicion in an infant with non-bilious emesis is the diagnosis of pyloric stenosis. If your differential diagnosis is rather broad, and you desire additional anatomic information, an upper GI should be ordered. HPS most commonly presents at 2-6 weeks of life, with 95% of cases seen by 12 weeks of life.

Q. Are there ultrasound services not offered at Primary Children's Ultrasound?

- A. Ultrasound services not currently offered:
- Breast US over 12 years old, or post-menarchal
 - Pelvic ultrasound to evaluate IUD position
 - Transvaginal ultrasound

*Please feel free to contact Primary Children's
Medical Imaging Department with any other questions.
(801) 662-1802*

